

A REVIEW OF 80 SUPERNUMERARY TEETH REMOVED UNDER GENERAL ANAESTHESIA

W.C. Ngeow, A.M. Anuar. A review of 80 supernumerary teeth removed under general anaesthesia. *Ann Dent Univ Malaya* 2004; 11: 7–12.

ABSTRACT

A retrospective study was carried out to review the records of 47 patients who had had in total 80 supernumerary teeth (ST) removed under general anaesthesia between 1975 and 2002. Malays made up 38.30%, Chinese 51.06%, and Indians 10.64% of the patients. The predominant age group was 6-10 year-old. The mean age was 12.96 ± 9.49 years. The male and female ratio was 1.35:1. Most of the patients had either one ST (n=31; 65.96%) or two ST (n=11; 23.40%). Five cases of multiple supernumeraries were recorded. Two patients experienced late formation of subsequent ST after the first surgery, thus requiring a second surgery.

The majority of ST were conical in shape (n=35; 43.75%). Most of the ST were located in the premaxilla (n=55; 68.8%). Almost a quarter (23.75%) of ST were inclined towards the oral cavity. Some of the effects on the dentition were diastema, cystic changes, rotation, displacement, and retention of the permanent teeth and these were the indications for removal of ST. The most common surgical approach for maxillary ST was from the labial, buccal or labio-buccal approach.

Key words: supernumerary, tooth, audit.

INTRODUCTION

Supernumerary teeth (ST) is the term used to describe “any tooth or structure seen in excess of the usual number for a given of the dental arch” (1). ST is a common dental anomaly. It occurs in the primary and permanent dentitions. The prevalence is generally between 0.3% to 3.5% in the permanent dentition but a percentage as high as between 5 to 9% has been reported (2). In the primary dentition, the prevalence is 0.8% (3).

In permanent dentition ST occurred twice as commonly in males than females (1,4). There is a greater number of ST in the maxilla as compared to the mandible. The ratio of ST in the maxilla to the mandible is between 6:1 and 11:1 (5,6). Koch *et al.* (7) found that premaxilla is the most common location affected.

The classification of ST can be done according to morphology and location (8). The morphology of

W.C. Ngeow¹, A.M. Anuar²

¹Associate Professor

²Dental Student

¹Department of Oral and Maxillofacial Surgery, Faculty of Dentistry, University of Malaya, 50603 Kuala Lumpur, Malaysia.

²Faculty of Dentistry, University of Malaya, 50603 Kuala Lumpur, Malaysia.

Corresponding author – Ngeow Wei Cheong

ST can be divided into four namely; conical, tubercle, supplemental, and odontome (8). In the permanent dentition, the most common supernumerary is the conical type (3,8,9). The majority of supernumeraries found in the primary dentition are the supplemental and conical types and they seldom remain impacted (8). The conical ST is usually found in the midline region of the anterior maxilla. Tuberculate is also found in the same location, but positioned more palatally than the conical form. These two types differ in both morphology and their effect upon the dentition and probable aetiology.

ST may appear to be single or multiple, erupted or impacted, and in one or both jaws (8). Multiple ST are usually associated with systemic diseases or syndromes such as Down's Syndrome, cleidocranial dysostosis, Gardner's Syndrome, cleft lip and palate, tricho-rhino-phalangeal syndrome and Fabry-Anderson's Syndrome (8,10–12). But there are studies that found that multiple ST can occur in non-syndrome patient (13).

Intraorally, it may be erupted or retained in the bone. The number, location and shape of the unerupted ST can be determined by the radiograph or clinical examination (14). Patient usually comes with clinical symptoms such as pain at the site of ST, retention or delayed eruption of permanent teeth, bulging on mucosa or erupted extra tooth and disturbance in occlusion (3,5,8,14). More unusually, ST has been discovered remote from the tooth bearing areas, e.g. in the nose and paranasal sinus (15) or between the orbit and brain (16).

Among the effect of ST on the dentition is malocclusion, crowding, displacement of permanent tooth that may vary from a mild rotation to complete displacement and failure of eruption of teeth especially central incisors in permanent and primary dentition (3,8,9,14,17). Some other features

indicating the presence of ST is median diastema or obvious rotations in the anterior maxilla (17).

Dentigerous cyst formation is another condition that may be associated with ST (7,17). Resorption of roots adjacent to a ST may occur but it is extremely rare (14,18).

MATERIALS AND METHODS

The records of patients who attended the Oral Surgery Clinic between 1975-2002 for removal of ST under general anaesthesia were retrieved based on entries in the Oral Surgery Operation Theatre Log Book.

The patients' sociodemography such as race, sex and age at operation were tabulated. The conditions of the ST namely, the number of teeth, their morphology, location in the jawbones and inclination were recorded. The morphology of the ST were recorded according to the notes in the patients' records and reconfirmed where possible by viewing available radiographs.

The indications for having ST removed surgically were tabulated. These included root resorption, interference in root formation, changes in eruption (displacement), spacing (diastema), retention, cystic changes and periodontal problem. Again, where possible, these signs were reconfirmed by viewing available radiographs.

The surgical approaches for removing ST under general anaesthesia were reviewed.

RESULTS

Only 47 records out of 75 entries were available for review. Altogether, these 47 patients presented with a total of 80 ST. Of these, 2 patients were detected with ST on two separate occasions. As a result, these patients underwent re-surgery because of the delayed eruption of ST following the first surgery. The ST reappeared after 2 and 4 years since the first detection and surgery. These new ST occurred at different locations of the jaw. For the sake of recording results, tabulation, and discussion, the authors decided to base the study on the number of patients, that is 47. Those cases with ST presenting at different times were recorded once only. A special note is placed upon these cases.

Half of the 47 operated patients were Chinese (n=24; 51.06%). The remaining patients were 18 Malays (38.30%) and 5 Indians (10.64%). There were 27 male and 20 female with ratio 1.35:1.

The mean age at the time of surgery was 12.96 ± 9.49 ; 14.85 ± 11.77 for male and 10.40 ± 4.06 for female. Predominant group for both sexes was the 6-10 year-old (Figure 1).

The majority of the patients (65.96%) had only one ST. Almost a quarter (23.40%) had 2 ST and one patient each had 3, 4 & 8 ST respectively. The remaining 2 patients had 6 ST. Average ST per person was 1.70 (Table 1). There are also 4 multiple ST cases in patients with no systemic disease or syndrome. The record for the remaining one patient with multiple ST was not clear enough to link or unlink with systemic disease.

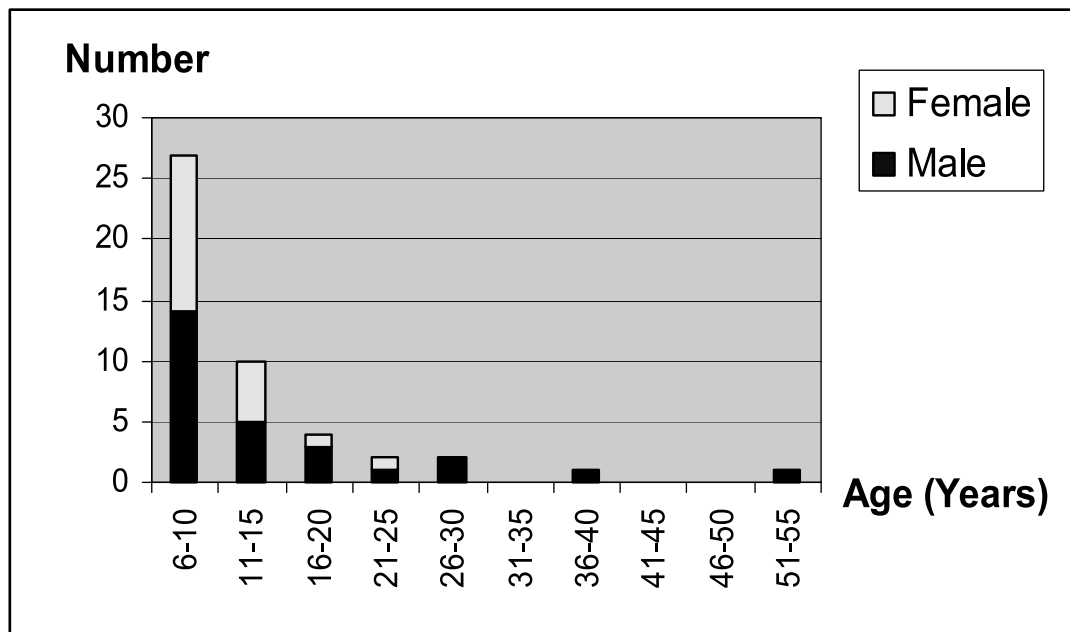


Figure 1: Age distribution of patient with ST according to sex.

Table 1. Number of ST per patient

Number of ST per person	Number of patients	Total number of ST
1	31	31
2	11	22
3	1	3
4	1	4
5	0	0
6	2	12
7	0	0
8	1	8
Total		80

Table 2. The inclination of the ST in the jawbones

Inclination	Number	Percentage %
Towards oral cavity	19	23.75
Inverted	26	32.50
Horizontal	2	2.50
No information	3	41.25
Total	80	100

It was noted that only 9 of the 19 ST that were inclined toward the oral cavity had erupted; two of these were found in primary dentition, 5 ST in mixed dentition and 2 ST in permanent dentition. The rest might be retained in bone because of obstruction by permanent teeth or because their positions were either inverted or horizontal (Table 2). Of the supernumeraries that had erupted, two were supplemental and the rest were conical in shape. Two of the ST erupted into the primary dentition.

Figure 2 illustrates the location of ST in relation to their location in the maxilla and mandible. All 55 ST in the anterior region were located in maxilla.

Mesiodens made up 23 of 55 ST that occurred in the anterior maxillary region. Mesiodens is the term normally used to describe conical ST located in the premaxillary region.

The most common morphology in these samples were conical (n=35, 43.75%), followed by supplemental (n=12, 15%) and tubercle (n=6; 7.5%) (Figure 3). The morphology of 27 ST was unknown because of incomplete information. No case of odontome was recorded. Two ST (2.5%) occurred in the primary dentition. These ST were mesiodens and conical in shape.

Table 3 lists the reasons for removal of ST under general anaesthesia. The main indication is the effect of ST on permanent teeth (diastema / rotation / retention / displacement) that can be seen clinically (n=29; 23.2%).

Table 4 lists the common surgical approach to remove ST. The labial / buccal / labio-buccal approach (n=31) was the most common, followed by palatal approach (n=23). However, detail of technical approach in 21 cases was not available.

DISCUSSION

In this study, a male to female ratio of 1.35:1 was found. The figure is lower than average sex ratio of 2:1 stated in the literature (1,4,19). The figure is almost equal in males and females because the sample is small and there were 28 folders that could not be retrieved. Moreover, this study does not look into ST that had been removed under local anaesthesia.

The predominant age of patients is between 6-10 years old. This finding is consistent with other reports like the study by Koch *et al.* (7) in which more than 50% of patients were between 5-9 years old, and von Arx (2) who reported a predominant age between 6-10 years old.

The mean age of 12 years 11.5 months (sd 9 years 5.9 months) recorded here is close to the 12.5

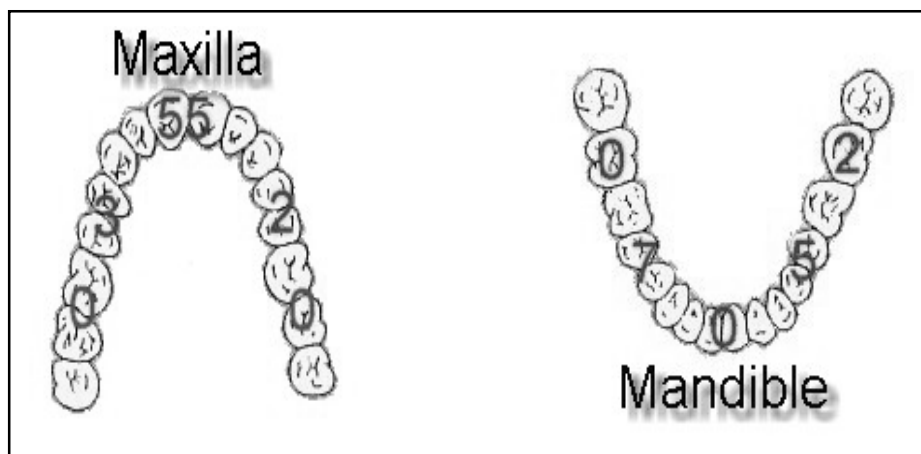


Figure 2: Location and number of ST in the maxilla and mandible.

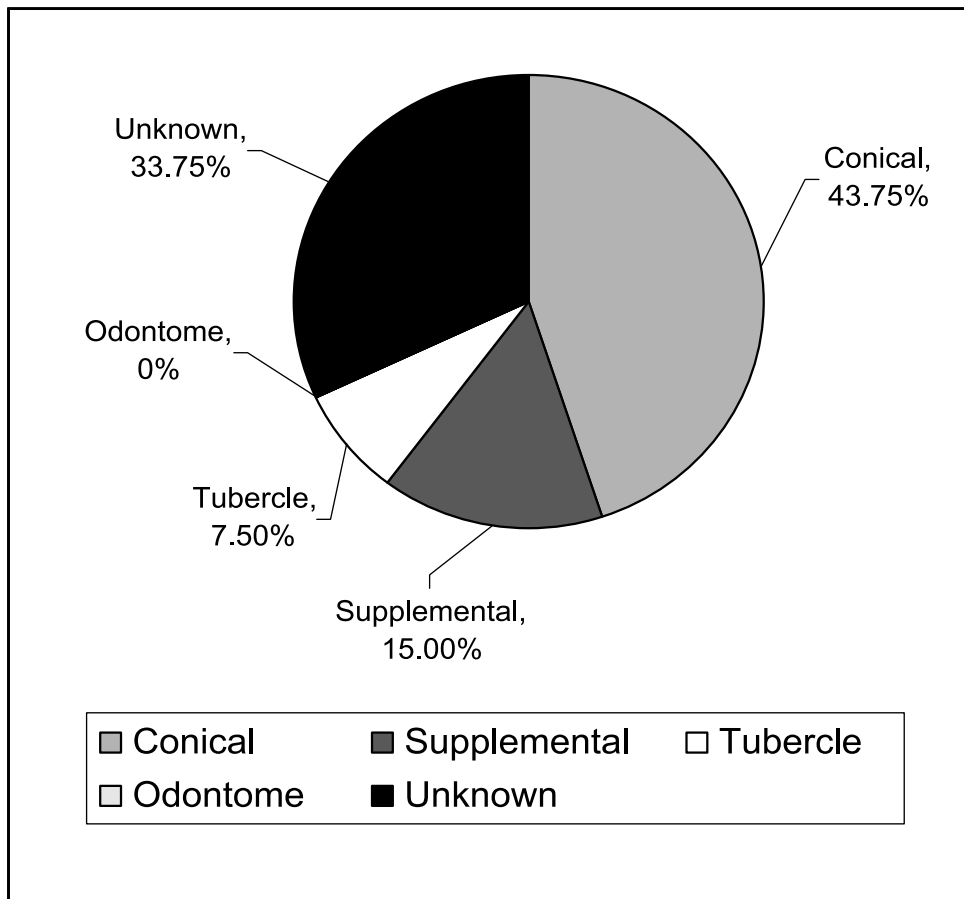


Figure 3: The morphology of supernumerary teeth.

Table 3. Indications for removal of ST

Indications	Number
Diastema	6
Rotation of permanent teeth	11
Retention of permanent teeth	8
Displacement of permanent teeth	5
Radiographic finding	13
Orthodontic consultation	10
Root resorption of permanent teeth	1
Interference in root formation	1
Speech defect	1
Eruption of ST	9
Cystic changes	5
Alveolar bone graft	2
Periodontal problem	1
Informed by dentist	4
Non vital teeth	1

Table 4. Surgical approaches for removal of ST

Surgical Approach	Number
Buccal	4
Labial	14
Palatal	23
Buccol-palatal	4
Labiol-palatal	0
Buccol-lingual	1
Buccol-labial	13
No information	21

years reported by Brook (1). In contrast, Mitchell & Bennett (20) reported a mean age of 9 years 5 months at time of removal of ST.

Most of the ST were found to be located in the maxilla and premaxilla areas, a finding similar to that by Primosh and Koch *et al.* (7,17). The next common site is the mandibular premolar area. This is in agreement with earlier observation by Mitchell (9) and Nazif *et al.* (21). In premolar region, the most

common form was the supplemental tooth. There were 2 ST in this region that had erupted. No case of distomolar was noted. In molar region, there was a paramolar and a molariform ST.

Most of the ST were conical in shape. The conical-shaped ST tend to displace the adjacent teeth rather than delay eruption (3,8).

In adult, usually it is because of cystic formation, incidental radiographic finding in investigation on impacted third molar status or caries that ST are found (2). In children, ST is detected because of delayed eruption, displacement of permanent teeth, and diastema (14). Other reason for indicating for removal of ST is for orthodontic treatment. Thus the finding of our study complies with these indications and confirmed an earlier finding by Nik-Hussein in the same center (14). Most of the cases were discovered in children and quite a high percentage was related to delayed eruption, displacement and diastema. Clinically, 7 of the unerupted ST were palpable, which presented with hard tissue swelling. The remaining unerupted ST were detected from radiographs.

There are four treatment options for supernumerary teeth according to Frank (22). There is no need for immediate indication for surgical removal of ST if no biological effect is seen. Koch *et al.* (7) reported a follow-up of 52 unerupted ST which were not removed surgically but presented with no biological lesion. The exact period for removal of ST is still controversial, because surgery will result in damage to the alveolar and periodontal tissues (23). Primosh was against any extraction in order to minimize any possibility in dislocation of tooth buds that may result in dislocation, malformation of root and loss of vitality of permanent dentition (17). It has been suggested that surgical removal is performed when the root formation of permanent teeth have completed to prevent iatrogenic damage (7). However, Hogstrom and Andersson (18) found that there was no evidence of root resorption during a three-year follow-up.

In this study, most of the surgical removal of ST were done right after the detection. The predominant group was 6-10 year-old, which meant the root of the anterior teeth and the crown of the posterior teeth were still in the state of development. No follow-up was done after the removal of ST except the standard 1-7 days post-operative review and treatment to expose the central incisors. As such, the authors are unable to determine the effect of surgical procedure on the permanent dentition.

There were 5 cases of multiple ST, with 4 of them located in the mandible. Most of these ST occurred in premolar region of the mandible. Yusof reported that premolar region of the mandible was the most common site for the occurrence of ST in non-syndrome multiple ST (13). We believe these cases comply with the non-syndrome multiple ST described by Yusof.

It has been claimed that most ST are lying palatally to the arch (2), so the majority of surgical approaches are from palatal side. Although, the authors found quite a significant number of ST that were approached from labial, buccal or labio-buccal for surgical removal, this predominance cannot be confirmed because the technical approach for 21 cases were not available.

In conclusion, the occurrence of ST in this center does not differ from those reported in the western literature. The only difference is the lack of multiple ST with syndromes reported.

ACKNOWLEDGEMENT

The data for this article was taken from an elective project undertaken at the Faculty of Dentistry, University of Malaya between 2002 and 2003.

REFERENCES

1. Brook AH. Dental anomalies of number, form, and size: their prevalence in British school children. *J Int Assoc Dent Child* 1974; 5: 37–53.
2. von Arx T. Anterior maxillary supernumerary teeth: a clinical and radiographic study. *Aust Dent J* 1992; 37: 189–95.
3. Crean SJ, Cunningham S, Coonar HS. Multiple Supernumeraries: a case report. *Dent Update* 1995; 22: 343–5.
4. Kinirons MJ. Unerupted premaxillary supernumerary teeth. A study of their occurrence in males and females. *Br Dent J* 1982; 153: 110.
5. Bodin I, Julin P, Tomsson M. Hyperdontia: I. Frequency and distribution of supernumerary teeth among 21,609 patients. *Dentomaxillofac Radiol* 1978; 7: 15–7.
6. Luten JR Jr. The prevalence of supernumerary teeth in primary and mixed dentitions. *J Dent Child* 1967; 34: 346–53.
7. Koch H, Schwartz O, Klausen B. Indications for surgical removal of supernumerary teeth in the premaxilla. *Int J Oral Maxillofac Surg* 1986; 15: 273–81.
8. Garvey MT, Barry HJ, Blake M. Supernumerary teeth – an overview of classification, diagnosis and management. *J Can Dent Assoc* 1999; 65: 612–6.
9. Mitchell L. Supernumerary teeth. *Dent Update* 1989; 16: 65–6, 68–9.

10. Gorlin RJ, Cohen MM Jr, Wolfson J. Trichorhino-phalangeal syndrome. *Am J Dis Child* 1969; 188: 595–599.
11. Regattieri LR, Parker JL. Supernumerary teeth associated with Fabry-Anderson's Syndrome. *Oral Surg Oral Med Oral Pathol* 1973; 35: 432–3.
12. Richardson A, Deussen FF. Facial and dental anomalies in cleidocranial dysplasia: a study of 17 cases. *Int J Paediatr Dent* 1994; 44: 225–31.
13. Yusof WZ. Non-syndrome multiple supernumerary teeth: literature review. *Canad Dent Assoc J* 1990; 56: 147–9.
14. Nik-Hussein NN. Supernumerary teeth in the premaxillary region: its effects on the eruption and occlusion of the permanent incisors. *Aust Orthod J* 1990; 1: 247–50.
15. Pracy JP, Williams HO, Montgomery PQ. Nasal teeth. *J Laryngol Otol* 1992; 106: 366–7.
16. Sjoberg S, Lorinc P. Intracranial supernumerary tooth. Case report. *Radiologe* 1984; 24: 561–3.
17. Primosch RE. Anterior supernumerary teeth – assessment and surgical intervention in children. *Pediatr Dent* 1981; 32: 204–15.
18. Hogstrom A, Andersson L. Complication related to surgical removal of anterior supernumerary teeth in children. *ASDC J Dent Child* 1987; 54: 341–3.
19. Kaler LC. Prevalence of mesiodens in a pediatric Hispanic population. *ASDC J Dent Child* 1988; 55: 137–8.
20. Mitchell L, Bennett TG. Supernumerary teeth causing delayed eruption – A Retrospective Study. *Br J Orthod* 1992; 19: 41–6.
21. Nazif MM, Ruffalo RC, Zullo T. Impacted supernumerary teeth: a survey of 50 cases. *J Am Dent Assoc* 1983; 106: 201–4.
22. Frank CA. Treatment options for impacted teeth. *J Am Dent Assoc* 2000; 131: 623–32.
23. Giancotti A, Grazzini F, De Dominicis F, Romanini G, Arcuri C. Multidisciplinary evaluation and clinical management of mesiodens. *J Clin Pediatr Dent* 2002; 26: 233–7.