

AN UNUSUAL PRESENTATION OF A RARE RHABDOMYOSARCOMA OF URINARY BLADDER AND PROSTATE - CASE REPORT

Shanggar K, Muhilan P, Dublin N, George Lee EG, Azad Hassan AR

Department of Surgery, Faculty of Medicine, University of Malaya, 50603 Kuala Lumpur, Malaysia.

ABSTRACT: Rhabdomyosarcoma of the genitourinary tract is rare and predominantly affects paediatric patients. We present an unusual case of such a lesion in an adult with extensive occupation of the bladder cavity by the lesion, resulting in bilateral ureteric obstruction, without evidence of ureteric outlet invasion. We outline the unusual CT and macroscopic appearance of this lesion. We also discuss the literature data and management strategies of rhabdomyosarcoma of the genitourinary tract. (*JUMMEC 2007; 10(2):57-59*)

KEYWORDS: Rhabdomyosarcoma, soft tissue sarcoma, prostate, bladder.

Introduction

Rhabdomyosarcoma (RMS) is a malignant tumour of skeletal muscle differentiation, and may affect organs with minimal or absent striated muscles such as urinary bladder, prostate and common bile duct. The bladder and prostate sites account for about 5% of all rhabdomyosarcomas, which is more prevalent in paediatric populations, but rare in adults (1). We highlight an unusual case of adult rhabdomyosarcoma of the urinary bladder with an unusual presentation.

Case Report

A 56-year-old man presented with haematuria preceding an episode of acute urinary retention. Initial IVU, during which the renal profile was normal, showed a large filling defect in the bladder with bilateral hydronephrosis and hydroureter (Figure 1). His renal function deteriorated despite catheterisation, and he was treated with haemodialysis and bilateral percutaneous nephrostomy, after which his renal function normalised. Cystoscopy confirmed presence of extensive bladder lesion, which occupied the whole bladder cavity, without room for endoscopic resection. The biopsy revealed a high grade sarcoma. Staging CT scan demonstrated an organ confined lesion, with no lymphadenopathy. The bladder was completely filled with the lesion, interfaced with air filled cavities (Figure 2). The patient subsequently underwent a radical cysto-prostatectomy with urinary diversion by ileal conduit. The intra-operative findings revealed a urinary bladder densely packed with lesion,

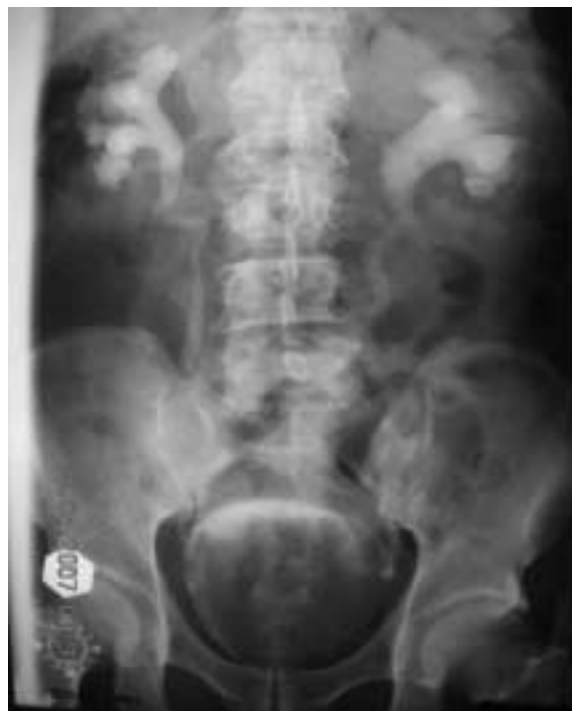

Figure 1. IVU showed a large filling defect in the bladder with bilateral hydronephrosis and hydroureter.

Correspondence:
Shanggar Kuppasamy
Department of Surgery,
Faculty of Medicine,
University of Malaya,
50603 Kuala Lumpur, Malaysia.
Email: drshanggar@um.edu.my

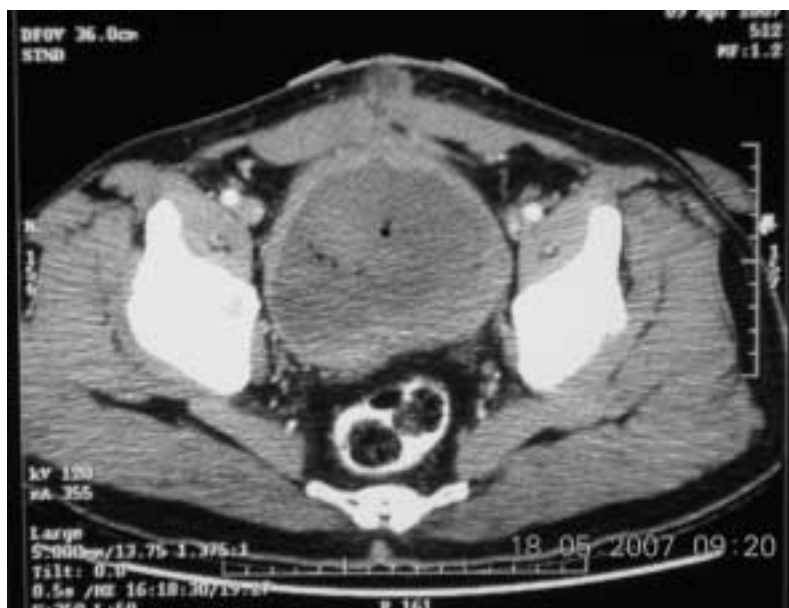

Figure 2. Staging CT scan demonstrated an organ confined lesion, with no lymphadenopathy. The bladder was completely filled with the lesion, interfaced with air filled cavities.

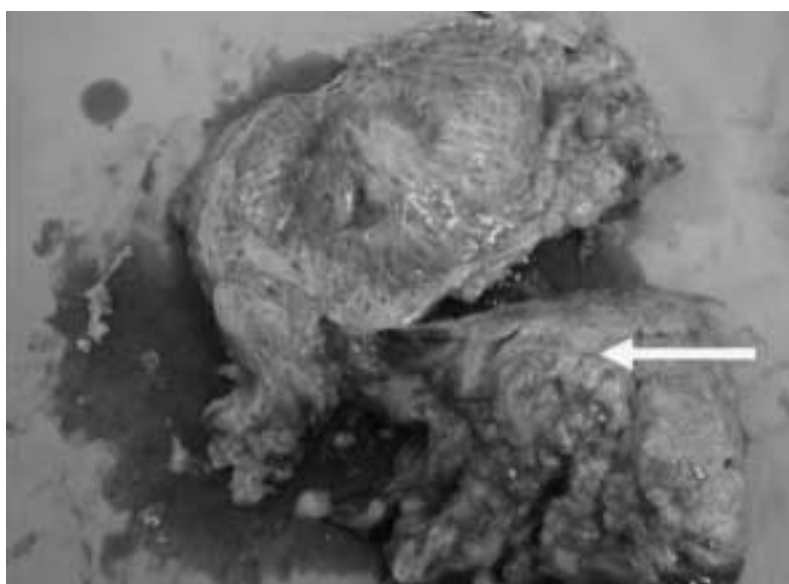


Figure 3. The macroscopic specimen revealed an extensive occupation of the lesion in the bladder cavity and with solitary site of tumour invasion (Arrow).

resulting in bilateral ureteric obstruction, without evidence of ureteric outlet invasion. The macroscopic specimen revealed an extensive occupation of the lesion in the bladder cavity, with solitary site of tumour invasion (Figure 3). The histopathology confirmed highly pleomorphic embryonal type of rhabdomyosarcoma involving the bladder and prostate. Distal end of both the ureters were free of tumour. The patient subsequently underwent adjuvant post-operative IVA regime chemotherapy, i.e., Ifosfomide (3gm/m²), Vincristine (1.5mg/m²) & Actinomycin D (1.5mg/m²) for 7 courses followed by 28 and 3 fractions of Radiotherapy to the pelvis and prostate respectively.

Discussion

Primary soft tissue sarcoma of the genitourinary tract in adults is very rare. In the United States, out of ten thousand newly diagnosed cases of soft tissue sarcoma in 2005, only 2.1% involved the genitourinary tract (2). The low incidence of this type of malignancy results in the lack of data available in our extensive literature search.

Leiomyosarcoma is the commonest type, and rhabdomyosarcoma is the least common histological type of soft tissue sarcoma. Bladder and prostate

rhabdomyosarcoma also accounts for 0.1% of all the soft tissue sarcoma (3, 4). Rhabdomyosarcoma can be divided into embryonal, alveolar and the pleomorphic types. Embryonal type is the most common, accounting for about 2/3 of cases. Pleomorphic type is very rare and seen only in adults. Prognosis is better in the embryonal type, especially the botryoid and spindle-cell variety (1).

Rhabdomyosarcoma of bladder and prostate predominantly affects the paediatric male patients, and usually present with haematuria and bladder outlet obstruction (3,5). The treatment option largely depends on the stage of the disease at the time of presentation. A well localised disease to the bladder/prostate confirmed by imaging modalities like CT scan is best treated with a radical resection. A complete resection with negative surgical margins (6) gives the best recurrence, progression and survival outcomes (6, 7, 8). The overall prognosis for the genitourinary soft tissue sarcoma is poor compared to the soft tissue sarcoma of other origins (8). The role of adjuvant doxorubicin chemotherapy has not been fully established (9). Although Doxorubicin-based chemotherapy are popular, e.g., VAC regime (Vincristine, Adriamycin and Cyclophosphamide), other regimes like IVA (Ifosfamide, Vincristine and Actinomycin D) and MAID regime (Mesna, Adriamycin, Ifosfamide and Dacarbazine) are also being administered but the success rates needs further evaluation (10).

Conclusion

Rhabdomyosarcoma of the bladder and prostate is a very rare entity and has very poor prognosis. A complete surgical resection in the form of a radical cystoprostatectomy with negative margins is recommended. This is essential to ensure a good outcome. The use of adjuvant chemotherapy needs further evaluation.

References:

1. Nigro KG, MacLennan GT. Rhabdomyosarcoma of the bladder and prostate. *J Urol* 2005; 173:1365.
2. Jemal A, Murray T, Ward E, et al. Cancer statistics. *CA Cancer. J Clin* 2005; 55: 10-30.
3. Zohar AD, Raanan T, Dragan G, et al. Adult genitourinary sarcoma: The 25-year Memorial Sloan-Kettering Experience. *J Urol* 2006; 176:2033-39.
4. Mondaini N, Palli D, Saieva C, et al. Clinical Characteristics and Overall Survival in Genitourinary Sarcomas Treated with Curative Intent: A Multicenter Study. *Eur Urol* 2005; 47: 468-73.
5. Jones CB, Oberman HA. Rhabdomyosarcoma of the bladder. Occurrence in childhood and in advanced age. *J Urol* 1964; 91:533-37.
6. Russo P, Brady MS, Colon K, et al. Adult urological sarcoma. *J Urol* 1992; 147:1032-37.
7. Catton CN, O'Sullivan B, Kotwall C, et al. Outcome and prognosis in retroperitoneal soft tissue sarcoma. *Int J Radiat Oncol Biol Phys* 1994; 29:1005-10.
8. Stojadinovic A, Leung DH, Hoos A, et al. Analysis of the prognostic significance of microscopic margins in 2,084 localised primary adult soft tissue sarcomas. *Ann Surg* 2002; 235:424-34.
9. Adjuvant chemotherapy for localised respectable soft tissue sarcoma of adults: Meta-analysis of individual data. [editorial]. Sarcoma Meta-Analysis Collaboration. *Lancet* 1997; 350:1647-54.
10. Nestor FE, Brian PR, Elizabeth HB, et al. Response to Chemotherapy and Predictors of Survival in Adults Rhabdomyosarcoma. *Ann Surg* 2001; 234(2): 215-23.